

Antibodies to Herpesvirus Nonvirion Antigens in Squamous Carcinomas

Author(s): Ariel C. Hollinshead, Obong Lee, Paul B. Chretien, John L. Tarpley, William E. Rawls and Ervin Adam

Source: *Science*, New Series, Vol. 182, No. 4113 (Nov. 16, 1973), pp. 713-715

Published by: [American Association for the Advancement of Science](#)

Stable URL: <http://www.jstor.org/stable/1737412>

Accessed: 30-07-2015 20:37 UTC

## REFERENCES

Linked references are available on JSTOR for this article:

[http://www.jstor.org/stable/1737412?seq=1&cid=pdf-reference#references\\_tab\\_contents](http://www.jstor.org/stable/1737412?seq=1&cid=pdf-reference#references_tab_contents)

You may need to log in to JSTOR to access the linked references.

---

Your use of the JSTOR archive indicates your acceptance of the Terms & Conditions of Use, available at <http://www.jstor.org/page/info/about/policies/terms.jsp>

JSTOR is a not-for-profit service that helps scholars, researchers, and students discover, use, and build upon a wide range of content in a trusted digital archive. We use information technology and tools to increase productivity and facilitate new forms of scholarship. For more information about JSTOR, please contact [support@jstor.org](mailto:support@jstor.org).



*American Association for the Advancement of Science* is collaborating with JSTOR to digitize, preserve and extend access to *Science*.

<http://www.jstor.org>

stained with hematoxylin and eosin, and blue after staining with aniline blue. The irregular, skeinlike appearance of the hyaline bodies clearly differentiated them from giant mitochondria, which are occasionally visible by light microscopy as regular, circumscribed, round, or ovoid cytoplasmic globules (1). Necrotic zones, containing numerous mononuclear and occasional polymorphonuclear inflammatory cells, were frequent around central veins. These areas showed conspicuous fibrosis, which occasionally obliterated the efferent veins. In some areas, thin fibrous septa connected adjacent central zones.

The entire constellation of histologic features characteristic of human alcoholic hepatitis has been produced for the first time in an experimental model. Moreover, the activity of serum transaminase was also increased, a common finding in alcoholic hepatitis. On the basis of early experiments with rats fed ethanol in drinking water (7), it was claimed by some that liver disease related to alcohol abuse is caused by associated malnutrition, and that a nutritionally fortified diet protects against the deleterious effects of chronic alcoholism. The data presented here indicate that not only fatty liver, but also alcoholic hepatitis, is a direct result of alcohol toxicity, and is not related to nutritional factors, since the diets of all animals contained excess protein, minerals, and vitamins. In man, alcohol-induced cirrhosis of the liver, often preceded by alcoholic hepatitis, usually follows 10 to 15 years of excess alcohol consumption (8). It is, therefore, not surprising that this irreversible phase of liver disease was not seen after only 9 months. It will be of interest to see whether the baboons eventually develop cirrhosis.

EMANUEL RUBIN

Department of Pathology,  
Mount Sinai School of Medicine,  
New York 10029

CHARLES S. LIEBER

Department of Medicine,  
Mount Sinai School of Medicine,  
and Section of Liver Disease and  
Nutrition, Veterans Administration  
Hospital, Bronx, New York 10463

#### References and Notes

1. E. Rubin, in *The Liver*, E. A. Gall and F. K. Mostofi, Eds. (Williams & Wilkins, Baltimore, 1973), pp. 199-217.
2. G. B. Phillips and C. S. Davidson, *Arch. Intern. Med.* **94**, 585 (1954); H. Popper, P. B. Szanto, M. Parthasarathy, *Am. J. Clin. Pathol.* **25**, 889 (1955).
3. H. A. Edmunson, R. L. Peters, T. B. Reynolds, O. T. Kuzma, *Ann. Intern. Med.* **59**, 646 (1963).
4. O. A. Iseri, C. S. Lieber, L. S. Gottlieb, *Am. J. Pathol.* **48**, 535 (1966); E. Rubin, P. Bacchin, H. Gang, C. S. Lieber, *Lab. Invest.* **22**, 569 (1970).
5. C. S. Lieber, D. P. Jones, L. M. DeCarli, *J. Clin. Invest.* **44**, 1009 (1965); E. Rubin and C. S. Lieber, *N. Engl. J. Med.* **278**, 869 (1968); C. S. Lieber and E. Rubin, *Am. J. Med.* **44**, 200 (1968).
6. The animals consumed daily 78 to 94 mg/kg of a diet which contained the following ingredients per liter: *d*- $\alpha$ -tocopherol acetate, 30 mg; thiamine hydrochloride, 1 mg; pyridoxine hydrochloride, 1 mg; folic acid, 1 mg; calcium pantothenate, 3 mg; nicotinic acid, 5 mg; ascorbic acid, 25 mg; choline chloride, 100 mg; inositol, 100 mg; *p*-aminobenzoic acid, 100 mg; vitamin B<sub>12</sub>, 1  $\mu$ g; vitamin A, 4000 international units (I.U.); vitamin D<sub>3</sub>, 400 I.U.
7. C. H. Best, W. S. Hartroft, C. C. Lucas, J. H. Ridout, *Br. Med. J.* **2**, 1001 (1949).
8. W. K. Leibach, *Acta Hepato-Splenol.* **14**, 9 (1967).
9. Supported in part by PHS grants AA00224, AA00287, and AM02511; the Veterans Administration; and the Laboratory for Experimental Medicine and Surgery in Primates.

28 June 1973; revised 30 July 1973

## Antibodies to Herpesvirus Nonvirion Antigens in Squamous Carcinomas

**Abstract.** Serums from tumor-bearing patients, cured patients, and normal subjects were examined for antibodies to the separated complement-fixing reactive components of nonvirion antigens of herpesvirus type 1 and type 2. The occurrence of antibodies to the antigens was similar in serums from tumor-bearing patients and cured patients. Antibodies to the antigens were observed among 21 of 24 (87 percent) cervical cancer cases, 44 of 49 (90 percent) laryngeal cancer cases, 15 of 24 (62 percent) cases of squamous cell carcinomas of the head and neck excluding the larynx, 2 of 24 (8 percent) nonsquamous cell cancer cases, and 3 of 51 (6 percent) normal subjects. By contrast, no differences were found in the titers of neutralizing antibodies to the virus in serums from laryngeal cancer patients and controls. The observations support an etiologic role of herpesviruses in cervical cancer and in laryngeal cancer, and possibly other squamous cell cancers of the head and neck.

Concentrates of purified antigens from viable cells from squamous cell carcinomas of the genital tract reacted in complement-fixation tests with antibodies present in the serums of patients with squamous cell cancers of the same site (1). With DNA tumor viruses, it has been possible to separate virus-induced, nonvirion antigens not only from tumors but also from cells undergoing lytic infection by the viruses (2). Separated antigens from squamous cell carcinomas of both the lip and cervix react specifically with antibodies to herpesvirus (HSV) nonvirion antigens (3). Antibodies to HSV nonvirion antigens have been detected in serums from patients with cervical cancer (3, 4), as well as patients with cancers of the lip (3), prostate, urinary bladder, kidney, and nasopharynx (5). Our study was undertaken to find out whether serums from patients with squamous cell cancers at various sites and with nonsquamous cell cancers contained anti-

bodies to HSV nonvirion antigens. In addition, the influence of successful therapy on the presence of antibodies to the above antigens was evaluated.

The tumor antigens were separated by a special method of polyacrylamide gel electrophoresis (PAGE) into three gel regions; cancer gel region 3, near the anodal end of the gels, was positive for complement-fixing (CF) reactivity with the antisera specific for HSV nonvirion antigens (6). With recent techniques of sequential, stepwise, low-frequency sonication, and subsequent centrifugation, the soluble portion of HSV nonvirion antigens has been studied with several strains of the virus (7). Analysis by PAGE of each sonicated fraction reveals the slow appearance of the genetic marker; after the final sonication all of the CF reactivity is present in the supernatant, with the final pellet being negative for CF reactivity (7). The portion of the supernatant separated by PAGE, which

Table 1. Comparison of antibodies to herpesvirus nonvirion (by complement fixation) and virion (by neutralization) antigens among patients with carcinoma of the larynx and normal persons.

Group	Tested (No.)	Mean age (years)	Antibodies to herpesvirus			
			Neutralization*		Positive CF†	
			Type 1	Type 2	No.	Percent
Carcinomas of larynx‡	38	59.5	2.17§	1.75§	36	95
Controls	36	58	2.19	1.82	2	5

\* Mean titers of neutralizing antibodies are as log<sub>10</sub>. One case and one control had no neutralizing antibodies to either virus. † Reactions in complement-fixation test to type 1 or type 2 (or both) nonvirion antigen. ‡ 91 percent nonvirion antigen-positive serums from tumor-bearing and 100 percent nonvirion antigen-positive serums from patients up to 4 years after treatment. Primary sites were 21 percent supraglottic and 79 percent glottic. § Data from (8).

Table 2. Antibodies to herpesvirus nonvirion antigens in relation to cancer type, site, and activity of disease; P, number positive; T, number tested.

Patient group	Squamous cell carcinomas						Nonsquamous cell cancers†		Normal subjects*	
	Larynx*		Other head and neck sites†		Uterine cervix		P/T	Positive (%)	P/T	Positive (%)
	P/T	Positive (%)	P/T	Positive (%)	P/T	Positive (%)				
Tumor-bearing	25/28	89	12/17	70	11/12	91	0/12	0		
Cured§	7/9	78	3/7	42	10/12	83	2/12	16		
Total	32/37	86	15/24	62	21/24	87	2/24	8	3/51	6

\* Includes some subjects shown in Table 1. † Specific cancer sites with number positive/number tested: tongue, 3/8; mouth and palate, 4/5; tonsil, 4/4; maxillary sinus, 3/3; pyriform sinus, 1/3; and gingiva, 0/1. ‡ Nonsquamous cell cancers include cases of melanoma (10), breast (4), salivary gland (4), rectum and colon (3), lacrimal gland (1), pancreas (1), and chondrosarcoma of the mandible (1). § Cured are patients who are disease-free four or more years after treatment.

is designated region 3, reacts specifically with absorbed antisera to HSV nonvirion antigens (6, 7). Although the soluble portions of the tumor antigens and the nonvirion antigens are different in composition, there are shared components of identity necessary for CF reactivity present in the gel regions 3 of both the preparations. Since the amount of antigen present in tumors varies, we chose to separate gel regions 3 from HSV type 1 (KOS strain) and HSV type 2 (SAV strain) nonvirion antigens.

Cultured human fetal kidney cells infected with HSV (35 plaque-forming units per cell) were harvested at 24 hours, disrupted with sonication (1 minute), and centrifuged at 100,000g for 1 hour. The pellets of both infected and noninfected cells were sequentially sonicated (low frequency, at 3, 1.5, and 1.5 minutes) and centrifuged at 100,000g. The supernatants were pooled, concentrated by ultrafiltration, and separated by PAGE (3, 6, 7). Separation by Sephadex gel filtration prior to PAGE as described earlier (1, 6) could be omitted. Region 3 of each gel was sliced, the protein was eluted, and the eluates were concentrated to uniform protein content by ultrafiltration and tested immediately.

Serums were collected in Houston, Texas, between October 1971 and June 1972 and stored at  $-35^{\circ}\text{C}$ ; the demographic attributes of these patients are described elsewhere (8). The National Cancer Institute (NCI) serums were collected within the past 3 months, passed through Millipore filters (0.4  $\mu\text{m}$ ), and stored in liquid nitrogen. Donors of serums collected at NCI were screened to exclude those receiving chemotherapy or radiotherapy or those with illnesses or on medications known to alter immune reactivity. The titers of antigens, complement, and serums were ascertained before use at selected concentrations in a standard macro CF test (1). Complement dilutions varied from 1:15 to 1:20 and

serums were tested at a dilution of 1:4. The region 3 protein content was regulated to 50  $\mu\text{g}$  per CF test for the serums from Baylor University; some positive CF tests were seen at this same protein concentration with the filtered serums from NCI, but it was necessary to repeat this test with 80  $\mu\text{g}$  of protein per CF test; the ratio of CF positive cancer serums to CF positive control serums was similar for both tests. All tests were uncoded after the completion of the final experiments.

Initially, serums from patients with laryngeal cancer and control subjects (8) were examined for antibodies to HSV nonvirion (from PAGE region 3) antigens, to region 3 cell antigens, and to virion antigens (Table 1). Antibodies to nonvirion antigens were found in 36 of 38 (95 percent) patients with laryngeal cancer and 2 of 36 (5 percent) control patients. No reactions were seen with control PAGE region 3 preparations. There were no differences between cancer cases and controls in antibodies to virus, as assayed by CF or by a microneutralization technique (9). Thus, the presence of antibodies to the HSV nonvirion antigens is associated with the laryngeal cancer and does not simply represent past infections with the herpesviruses.

To further clarify the relations of antibodies to the nonvirion antigens, we examined another group of patients with different types of malignancies at various sites. Some of this group were tumor-bearing patients, and others had been cured of their disease. Among squamous cell cancer patients, little difference was found between tumor-bearing patients and those clinically cured of cancer (Table 2); serums from 48 of 57 (84 percent) tumor-bearing and 20 of 28 (71 percent) cured patients showed CF reactivity with nonvirion antigens of region 3. Antibodies to the nonvirion antigens were present in the serums of 21 of 24 (87 percent) women with carcinoma of the cervix. Only 2 of 24 (8 percent)

patients with nonsquamous cell cancers had antibodies to the antigens. Serums from 15 of 24 (62 percent) patients with squamous cell cancers of the head and neck other than larynx reacted to the antigens.

We observed no pattern of preferential reactivity to the nonvirion antigens induced by type 1 HSV (HSV<sub>1</sub>) or type 2 HSV (HSV<sub>2</sub>). Serums reacted to only HSV<sub>1</sub> antigen in 18 percent of the serums that had antibodies and to only HSV<sub>2</sub> antigen in 5 percent of the serums which had antibodies. The remaining positive serums reacted with both antigen preparations.

The high occurrence of antibodies to HSV nonvirion antigens among patients with squamous cell carcinomas but not among normal subjects or patients with nonsquamous cell cancers suggests an association between the HSV and squamous cell lesions. The finding of antibodies to the nonvirion antigens in serums of patients with cervical cancer confirms previous reports (1, 3, 4).

Patients with laryngeal carcinomas were also found to have antibodies to the nonvirion antigens, suggesting an etiologic role of HSV in carcinomas of this site. Herpesvirus type 1 is primarily transmitted by the oral-respiratory route, while HSV<sub>2</sub> is venereally transmitted. Laryngeal cancer cases were similar to controls in the sexual and reproduction-associated factors associated with sexual promiscuity (8). This observation and the pattern of neutralizing antibodies to the two viruses shown in Table 1 suggests that the orally transmitted type 1 virus would be the most likely candidate. Antibodies to HSV nonvirion antigens were found among patients with squamous cell cancers of the head and neck other than the larynx, but the numbers studied were not sufficient to establish an association between the herpesviruses and each site.

Although most of the serums with antibodies to the nonvirion antigens re-

acted to antigens induced by both HSV<sub>1</sub> and HSV<sub>2</sub>, some serums reacted to one but not to the other antigen. The antigens of the two types appear to contain common and specific antigenic sites (7). The exact nature of the antigens and the relatedness between the two types of HSV remain unknown. Certain cytomegalic virus strains have been isolated from primary lung cancer cell cultures; there are indications that other members of the HSV group infecting humans induce similar antigens (10). The relation between the antigens of the HSV group, however, has not been established.

The continued presence of antibodies to the nonvirion antigens after successful treatment of the malignancy paralleled the finding of a high incidence of cellular immune abnormalities in both tumor-bearing and cured squamous carcinoma patients (11). If the antibodies were produced to antigens related specifically to the tumor cells, removal of the tumor should eliminate the antigen source and result in a subsequent disappearance of antibodies. However, removal of the malignancy may not eliminate all cells producing the antigens; clinically normal adjacent mucosa may, nevertheless, contain transformed cells. This may explain the well-documented, repeated development of new primary squamous cell carcinomas in these patients. On the other hand, cells in the premalignant stage of the disease might remain, or nonmalignant cells lytically infected with virus during recurrent infection might provide an antigen source for continued antibody stimulation. For these reasons it is important to determine the relations of antibodies to the antigens, to each other, and to the cancer. Similarly, a possible relation between expression of nonvirion antigens and the prolonged immune cellular abnormalities in the squamous cell cancer patients deserves attention. Further knowledge of the rates of antibody appearance and cancer development is necessary before the techniques can be applied clinically.

ARIEL C. HOLLINSHEAD, OBONG LEE  
Laboratory for Virus and Cancer  
Research, Department of Medicine,  
George Washington University,  
Washington, D.C. 20037

PAUL B. CHRETIEN, JOHN L. TARPLEY  
Surgery Branch, National Cancer  
Institute, Bethesda, Maryland 20014

WILLIAM E. RAWLS, ERVIN ADAM  
Departments of Virology and  
Epidemiology, Baylor University  
College of Medicine, Texas Medical  
Center, Houston 77025

16 NOVEMBER 1973

#### References and Notes

1. A. Hollinshead, J. Melnick, W. Rawls, *Int. Virol.* **2**, 105 (1971); A. Hollinshead, O. Lee, W. McKelway, J. Melnick, W. Rawls, *Proc. Soc. Exp. Biol. Med.* **141**, 688 (1972).
2. A. Hollinshead, T. Alford, S. Orozlan, H. Turner, R. Huebner, *Proc. Nat. Acad. Sci. U.S.A.* **59**, 385 (1968); A. Hollinshead and T. Alford, *J. Gen. Virol.* **5**, 411 (1969); A. Hollinshead, J. McCammon, D. Yohn, *Can. J. Microbiol.* **18**, 1365 (1972); G. Tarro and A. Sabin, *Proc. Nat. Acad. Sci. U.S.A.* **65**, 753 (1970).
3. A. Hollinshead and G. Tarro, *Science* **179**, 698 (1973).
4. G. Tarro, *Giornale Mal. Infet. Parassit.* **23**, 752 (1971); G. Tarro, Proceedings of the Seventh Meeting of the European Tumor Virus Group, Zierikzee, Netherlands, 1972; L. Aurelian, B. Schumann, R. Marcus, H. Davis, *Cancer Res.*, in press.
5. G. Tarro and A. Battista, *Excerpta Med.* **275**, 120 (1973) (abstr.); A. Sabin and G. Tarro, in preparation.
6. A. Hollinshead, *J. Nat. Cancer Inst. Monogr.* **37**, 306 (1973); A. Hollinshead, G. Tarro, W. Foster, L. Seigel, W. Jaffurs, *ibid.*, in press.
7. G. Tarro and A. Hollinshead, in preparation.
8. R. Sessions, H. Goepfert, E. Adam, W. Rawls, *Arch. Otolaryngol.*, in press.
9. W. Rawls, K. Iwamoto, E. Adam, J. Melnick, *J. Immunol.* **104**, 599 (1970).
10. A. Hollinshead and B. Eddy, in preparation.
11. P. Twomey, W. Catalona, P. Chretien, *Cancer*, in press.
12. Supported by National Cancer Institute contracts 69-2176 and NO1CP 33257 and American Cancer Society grant C123A. We thank Dr. J. Melnick, R. Sessions, and H. Goepfert for advice; and K. Tanner and P. Jones for technical assistance.

20 June 1973

## Grazing by the Echinoid *Diadema antillarum* Philippi: Formation of Halos around West Indian Patch Reefs

**Abstract.** *Between patch reefs and marine grass communities there is normally a zone or "halo" of heavily grazed grass 2 to 10 meters wide. Grazing by the echinoid *Diadema antillarum* Philippi during nocturnal migrations off the reefs is found to be the major factor in the formation of halos.*

A common feature associated with patch reefs in the West Indies is a band of nearly bare sand between the base of the reef and the outlying beds of marine monocotyledons *Thalassia testudinum* (turtle grass) and *Syringodium filiforme* (manatee grass). This so-called halo is commonly 2 to 10 m in width and is reminiscent of the bare zones reported between California shrub and grassland communities (1). Generally, the area closest to the reef is totally barren. The portion of the halo closest to the outlying beds of sea grasses usually has a moderate density of closely cropped plants and appears bare when viewed from afar or in aerial photographs (2).

Some attention has been paid to the origin of these halos. Previously it was

held that certain physical factors such as large particle size and rapidly shifting sands made growing conditions unfavorable in halos. However, it was found that halos were present over a wide range of physical environments. Neither the slope of the bare area, nor exposure to high-energy wave surge had any bearing on the presence or absence of the halo. Furthermore, analysis of the sediment revealed little difference in particle size between areas on the halo and areas in the grass beds (2).

Randall (2) presents some evidence that grazing fish—primarily surgeonfish (Acanthuridae) and parrot fish (Scaridae)—are responsible for the absence of vegetation in the halos. Recent observations have cast doubt on the extent to which herbivorous fish are responsible for halo formation and maintenance. First, grazing fish in the area of patch reefs on St. Croix, U.S. Virgin Islands, are under intense fishing pressure and are not common. Second, close observation of the short cropped grass within the halos surrounding these patch reefs shows that many of the blades do not display the scalloped edges characteristic of fish grazing. Rather, the blades are terminated in the ripped and jagged form which characterizes grazing by the echinoid *Diadema antillarum* Philippi (3, 4).

In the West Indies, *D. antillarum* is found in abundance on patch and barrier reefs (5). It remains inactive on

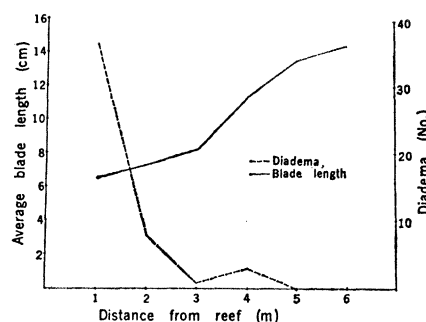


Fig. 1. Mean blade length of *Thalassia* and number of *Diadema* per meter (total of five midnight counts on each of four transects) as functions of distance from the reef edge. The distance 4 m corresponds to the visual edge of the halo. The data were taken in December 1972.